

MANEJO ODONTOLÓGICO PARA PACIENTES SUBMETIDOS À CIRURGIA DE VALVA CARDÍACA

O artigo publicado procurou revisar as diretrizes atuais e as melhores práticas para o manejo odontológico para os pacientes submetidos a cirurgia cardíaca valvar que expõe os pacientes a um risco aumentado de infecção pós-operatória como a Endocardite Infecciosa (EI).

A infecção da cavidade bucal é reconhecida como uma causa potencial de bacteremia que contribui para a ocorrência de EI.⁵⁻¹² Estima-se que aproximadamente 10-20% dos casos de EI estão relacionados a focos bucais.⁵⁻¹² Pacientes com próteses valvares mecânicas, frequentemente, recebem terapia anticoagulante contínua e / ou antiplaquetária,¹⁶⁻¹⁸ que expõe a um risco aumentado de sangramento durante o tratamento odontológico.

Estudos anteriores demonstraram que mais da metade dos pacientes requerem extração dentária e aproximadamente 50% exigem terapia periodontal antes da cirurgia valvar.¹⁹ Isso ressalta a necessidade de estabelecer protocolos para o atendimento odontológico de pacientes submetidos à cirurgia valvar cardíaca.

Neste estudo, revisamos a estratégia para o manejo odontológico dos pacientes incluindo o tempo necessário para o preparo odontológico; a gravidade dos pacientes subjacentes à condição cardíaca; a profilaxia antibiótica, anticoagulante e terapia antiplaquetária.

O objetivo da avaliação odontológica inicial é identificar focos infecciosos bucais, como cárie, doença periodontal e endodôntica, lesões mucosas e intra-ósseas na região maxilofacial, bem como tratar qualquer processo ativo.^{19,20,22,23} Os exames radiográficos sempre devem ser realizados.

A profilaxia antibiótica deve ser realizada 30-60 min antes dos procedimentos dentários associados a um risco elevado de bacteremia, incluindo procedimentos que envolvem manipulação de tecido gengival, manipulação da região periapical dos dentes e perfuração da mucosa oral, conforme recomendações da American Heart Association (AHA).²⁶

A literatura atual não recomenda interromper o uso de anticoagulante para realizar cirurgias orais menores, como extrações dentárias, biópsia e procedimentos periodontais em que o sangramento é facilmente controlado,^{17,29,31-34} para uma razão internacional normalizada (INR) de até 3,5 dentro de 72 h antes do procedimento.³¹⁻³³ Em o caso de

valores superiores a 3,5, o paciente deve ser encaminhado para o médico para ajustar a dose de medicação (Figura 1) .^{19,20}

Para pacientes que recebem heparina de baixo peso molecular (HBPM), a recomendação atual é suspender a terapia 12-24 h antes do tratamento odontológico invasivo.¹⁸ Nos casos em que existe um baixo risco de sangramento, (HBPM) pode ser reinstituído 4-6 h após o procedimento odontológico (Figura 1) .^{18,42,43} Para o manejo anticoagulante de pacientes submetidos a terapia intravenosa de heparina não fraccionada (HNF) recomenda-se descontinuar doses terapêuticas de HNF 4 h antes e avalie o tempo de tromboplastina parcial ativado. A terapia terapêutica com HNF pode ser reiniciada 12 horas após a cirurgia.^{18,42}

Não é recomendado que o ácido acetilsalicílico seja interrompido antes de procedimentos dentários (Figura 1).^{33,44} Em caso de procedimentos cirúrgicos, se necessário, hemostáticos locais adicionais devem ser utilizadas medidas.

Nos pacientes com a contagem de plaquetas inferior a 50 000 células / mm³, procedimentos invasivos devem ser adiados e a transfusão de plaquetas pode ser seja indicado antes do procedimento (Figura 1) .⁴⁸ Para pacientes hospitalizados os pacientes devem ter sinais vitais monitorados, incluindo PA, FC, FR e SatO₂. Pacientes hospitalizados em uso de drogas vasoativas e com co-morbidades como IRC, DM e ICC deve ser monitorizados por um anestesista e o procedimento realizado em bloco cirúrgico.


O uso de anestésicos com vasoconstritores como lidocaína 2% com epinefrina 1: 100 000 é uma opção segura para os pacientes.⁴⁹⁻⁵¹ O número é limitado a dois frascos.^{49,51}

Durante alguns procedimentos dentários, pode ser necessário usar medidas hemostáticas, como compressão de gaze, suturas, gelatina ou esponjas de colágeno.^{34,43,44} Substâncias antifibrinolíticas como ácido tranexâmico pode ser administrado.⁵² Os pacientes devem usar enxaguatório bucal lavando com 4,8% solução de concentração por 2 minutos quatro vezes ao dia, durante 1 semana.^{34,52}

. Fatores importantes a serem avaliados incluem o gravidade da doença cardiovascular e dentária subjacente, o tempo necessário para qualquer intervenção dentária, e, se alguma alternativa, menos procedimentos invasivos podem ser realizados para temporizar os problemas dentários.

REVIEW ARTICLE

Dental management for patients undergoing heart valve surgery

Alessandra F. Souza¹ | Amanda L. Rocha² | Wagner H. Castro² |
Claudio L. Gelape³ | Maria Carmo P. Nunes³ | Sicilia R. Oliveira² |
Denise V. Travassos¹ | Tarcília A. Silva² 

¹ Faculty of Dentistry, Department of Community and Preventive Dentistry, Universidade Federal de Minas Gerais, Minas Gerais, Brazil

² Faculty of Dentistry, Department of Oral Surgery and Pathology, Universidade Federal de Minas Gerais, Minas Gerais, Brazil

³ Faculty of Medicine, Department of Surgery, Universidade Federal de Minas Gerais, Minas Gerais, Brazil

Correspondence

Tarcília A. Silva, Faculty of Dentistry, Department of Oral Surgery and Pathology, Universidade Federal de Minas Gerais – UFMG – Av. Presidente Antônio Carlos, 6627 – Pampulha, Belo Horizonte – MG 31270-901, Brazil.

Email: silva.tarcilia@gmail.com

Funding information

Fundação de Amparo A PESQUISA DO ESTADO DE MINAS GERAIS

Abstract

This study sought to review current guidelines and the most optimal dental management for patients undergoing cardiac valve surgery.

KEYWORDS

dental prophylaxis for cardiac surgery, endocarditis

1 | INTRODUCTION

Cardiac valve surgery, involving both native and prosthetic valves, exposes patients to an increased risk of post-operative Infective Endocarditis (IE).¹⁻⁴ Infection of the oral cavity is recognized as a potential cause of bacteremia contributing to the occurrence of IE.⁵⁻¹² It is estimated that approximately 10-20% of IE cases are related to an oral foci⁵⁻¹² and the presence of chronic periodontitis increases the risk of IE, particularly in patients with heart defects.¹³⁻¹⁵

Patients with mechanical prosthetic heart valves often receive continuous anticoagulant and/or antiplatelet therapy,¹⁶⁻¹⁸ which exposes them to an increased risk of bleeding during dental treatment.

Previous studies have demonstrated that more than half of patients require tooth extraction and approximately 50% required periodontal therapy prior to valve surgery.¹⁹ This highlights the need to establish

protocols for the dental care of patients undergoing heart valve surgery. In this study, we review the dental management strategy for patients who require valve surgery, including time required for dental preparation; the severity of the patients underlying cardiac condition; and the management of antibiotic, anticoagulant, and antiplatelet therapy.

1.1 | Baseline assessment and dental planning

It is recommended that all patients undergoing cardiac valve surgery be referred for an initial dental evaluation¹⁹⁻²² which consists of a complete history and review of medications and allergies, as well as a complete oral and dental examination with appropriate radiographic examinations.

The aim of this first appointment is to identify oral infectious foci, such as caries, periodontal and endodontic disease, or mucosal and

intraosseous lesions in the maxillofacial region as well as to treat any active processes.^{19,20,22,23} Chronic non-infectious diseases and aesthetic restorations can be postponed to the post-operative period.²⁴

The oral mucosa, teeth, gums, and alveolar bone must be carefully evaluated. Radiographic examinations should always be performed. Panoramic images are indicated for general evaluation. If there is clinical evidence of periodontal disease or carious lesions, bite-wing and periapical radiographs must also be taken. Edentulous patients should undergo an oral mucosal and panoramic radiograph examination.^{19,21}

The dental treatment involves the removal of residual root fragments and the removal of teeth with periapical lesions and/or advanced periodontal disease, defined as a pocket depth ≥ 6 mm and/or attachment loss less than half of the root length (mobility grades 3 and 4). Teeth with an unfavorable prognosis must be extracted.¹⁹⁻²¹ Teeth with periodontitis, but without these signs and symptoms of infection should be observed, and tooth brushing instruction and/or scaling should be provided.²⁵ Removal of carious lesions and placement of permanent or temporary restorations should be performed. Teeth with manageable periapical lesions should receive endodontic treatment.¹⁹⁻²¹ However, if the time prior to cardiac surgery is insufficient for endodontic treatment, temporary root canal fillings with calcium hydroxide paste is recommended.²⁵

Infectious or inflammatory mucosal lesions should be treated as well as their underlining causes (eg, trauma, unsatisfactory prosthesis). Previously treated lesions and non-neoplastic proliferative processes that did not respond to therapy require biopsy for appropriate diagnosis and treatment. Following surgery, patients should be followed as an outpatient every 6 months or less depending on the individual patient's dental and periodontal condition.

1.2 | Antibiotic prophylaxis

Patients who are at high-risk for IE and must receive antibiotic prophylaxis before dental procedures are described in Table 1. This

includes patients with a history of previous IE, prosthetic heart valves, congenital heart disease, and heart transplants that developed valvular dysfunction.²⁶ Although the American Heart Association/American College of Cardiology guidelines recommend prophylaxis in cardiac transplant recipients who develop cardiac valvulopathy, this recommendation is not supported by others.^{27,28} Prophylaxis should be performed 30-60 min before dental procedures associated with a high-risk of bacteremia, including procedures which involve manipulation of gingival tissue, manipulation of the periapical region of teeth, and perforation of the oral mucosa.^{26,28-30} The procedures with potential risk to induce bacteremia are described in Table 2.

1.3 | Anticoagulant therapy

The current literature does not recommend discontinuing the use of anticoagulant medicine for performing minor oral surgeries, such as tooth extractions, biopsy, and periodontal procedures where bleeding is easily controlled,^{17,29,31-34} for an international normalized ratio (INR) value up to 3.5 within 72 h prior to invasive dental treatment.³¹⁻³³ In the case of values higher than 3.5, the patient should be referred to the physician to adjust the dose of medication (Figure 1).^{19,20} On the other hand, INR values below the therapeutic target exposes patients to an increased risk for thromboembolic events and medical intervention prior to dental treatment is indicated.³⁴

Patients with a mechanical prosthetic valve are recommended to receive anticoagulation with Vitamin K antagonists (VKA) and INR monitoring.²⁹ Anticoagulation with a VKA to achieve an INR of 2.5 is recommended in patients with no risk factors for thromboembolism.³⁵ For patients with additional risk factors for thromboembolic events, the goal is for an INR of 3.0.³⁵

The management of patients requiring minor dental surgery who present with an INR below 3.0 includes continued anticoagulated therapy without dose adjustment.³⁶ Uncomplicated extraction of 1-3 teeth was found to be acceptable for patients with an INR value up to

TABLE 1 Antibiotic prophylactic regimens for dental procedures

Situation	Agent	Regimen—single dose 30-60 min before procedure	
		Adults	Children
Oral	Amoxicillin	2 g	50 mg/kg
Unable to take oral medication	Ampicillin OR	2 g IM or IV ^a	50 mg/kg IM or IV
	Cefazolin or ceftriaxone	1 g IM or IV	50 mg/kg IM or IV
Allergic to penicillins or ampicillin—oral regimen	Cephalexin ^{b,c} OR	2 g	50 mg/kg
	Clindamycin OR	600 mg	20 mg/kg
	Azithromycin or clarithromycin	500 mg	15 mg/kg
Allergic to penicillins or ampicillin and unable to take oral medication	Cefazolin or ceftriaxone ^c	1 g IM or IV	50 mg/kg IM or IV
	OR Clindamycin	600 mg IM or IV	20 mg/kg IM or IV

^aIM, intramuscular; IV, intravenous.

^bOr other first or second generation oral cephalosporin in equivalent adult or pediatric dosage.

^cCephalosporins should not be used in an individual with a history of anaphylaxis, angioedema, or urticaria with penicillins or ampicillin. Wilson et al⁶; Nishimura et al²⁶; Habib et al.²⁷

TABLE 2 Probability of dental procedures causing bacteremia

High probability of significant bacteremia	Low probability of significant bacteremia
Procedures involving perforation of the oral mucosa	Local anesthesia
Tooth extraction	Fluoride and sealants application
Biopsy	Restorative dentistry procedures
Periodontal procedures (surgery, scaling, root planning, probing)	Placement of rubber dam and intracanal medication
Endodontic instrumentation	Suture removal
Intraligamentary anesthesia	Natural exfoliation of deciduous teeth

Adapted from Dajani et al³⁰; Wilson et al⁶; Nishimura et al^{26,29}; Habib et al.²⁷

3.5.^{16,37} Recently, studies from the North West Medicines Information Centre and British Association of Oral and Maxillofacial Surgeons have demonstrated that dental surgery can be safely performed with therapeutic levels of anticoagulation up to INR 4.0.^{17,38,39}

Furthermore, in the study conducted by Salam and colleagues, post-operative hemorrhage was not associated with the dose of warfarin or duration of its use.³⁹ Others studies have shown that patients receiving anticoagulation therapy, who undergo surgical procedures,

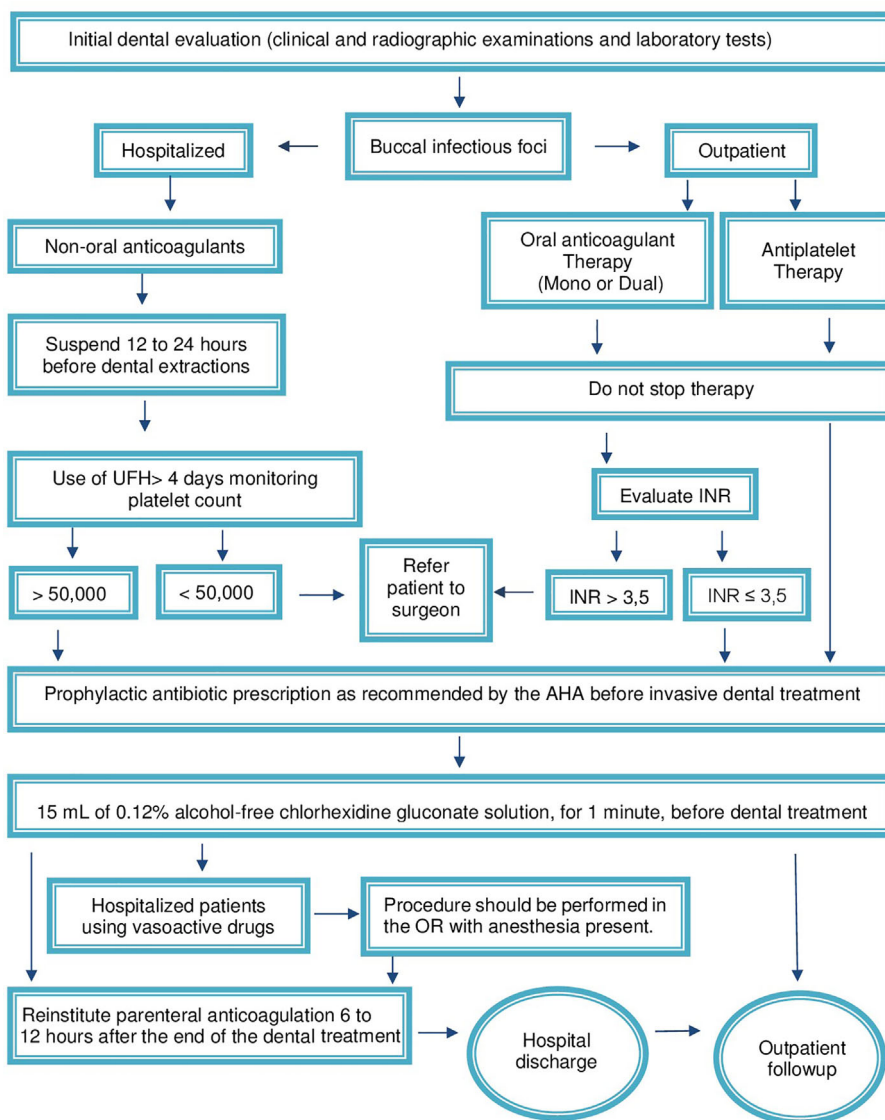


FIGURE 1 Dental management algorithm for patients undergoing heart valve surgery. AF, atrial fibrillation; AHA, American Heart Association; INR, international randomized ratio; OR, operating room; Periop, perioperative; Postop, postoperative; UFH, unfractionated heparin

have a low rate of hemorrhagic complications, and when these complications are present, they are managed with local hemostatic measures and may be treated at home.^{16,39–41}

For patients receiving low-molecular-weight heparin (LMWH), the current recommendation is to suspend the therapy 12–24 h before invasive dental treatment.¹⁸ In cases where there is a low risk of bleeding, LMWH can be reinstated 4–6 h after the completion of the dental procedure (Figure 1).^{18,42,43} For anticoagulation management of patients undergoing unfractionated heparin (UFH) intravenous therapy, it is recommended to discontinue therapeutic UFH doses 4 h prior to the procedure and measure an activated partial thromboplastin time. Therapeutic UFH therapy can be restarted 12 h after major surgery, but should be delayed longer in the presence of continued bleeding.^{18,42}

1.4 | Antiplatelet therapy

It is not recommended that acetylsalicylic acid be stopped prior to dental procedures (Figure 1) and that no bleeding test is indicated.^{33,44} In case of surgical procedures, if necessary, additional local hemostatic measures should be used, as described below.

Figure 1 is an algorithm for dental management of patients undergoing heart valve surgery.

1.5 | Dental treatment during hospitalization

The management of patients with heart valve disease can be performed in outpatient clinics or during hospitalization. The timing of the planned cardiac surgery, medical status of the patient, and the complexity of the proposed dental procedures will dictate whether the dental procedure should be performed as an outpatient or an inpatient.

The antibiotic prophylaxis should follow current guidelines as detailed in Table 1,^{1,26,27} before invasive procedures, for example, periodontal procedures, perforation of the oral mucosa, tooth extractions, biopsies, and endodontic instrumentation. 15 mL of 0.12% alcohol-free chlorhexidine gluconate solution should be used to rinse the mouth for 1 min before starting the dental treatment.⁴⁵ Several studies have demonstrated the efficacy of chlorhexidine mouthwash prior to dental procedures, showing that its use results in a significant reduction of bacteremia.^{12,46,47}

For hospitalized patients undergoing non-oral anticoagulation therapy with heparin (LMHW, UFH), these medications must be stopped 12–24 h before invasive procedures. Anticoagulation therapy can be reinstated 6–12 h after completion of the dental surgical treatment.^{18,42,43} If the platelet count is less than 50 000 cells/mm³, invasive procedures should be postponed and platelet transfusion may be indicated prior to the procedure (Figure 1).⁴⁸

During the treatment, the patients should have vital signs monitored including blood pressure, heart rate and respirations, and oxygen saturation. Hospitalized patients on vasoactive drugs and with co-morbidities such as chronic renal failure, diabetes mellitus, and congestive heart failure, should be monitored by an anesthesiologist and the procedure performed in the operating room.

The use of anesthetics with vasoconstrictors such as lidocaine 2% with epinephrine 1: 100 000 is a safe option for patients with heart disease.^{49–51} In healthy, non-cardiac patients, it can be administered up to 4.4 mg of lidocaine 2% per kilogram of weight, with the maximum dose limited to 300 mg.⁵⁰ However, among cardiac patients, when using it with epinephrine 1:100 000, the number is limited to two vials.^{49,51}

Patients on penicillin therapy for treatment of infections or for long-term secondary prevention of rheumatic fever are more likely to develop resistance to bacteria. Therefore, the recommended antibiotics for prophylaxis are clindamycin, azithromycin, or clarithromycin (Table 1).⁶

In the case of prolonged dental intervention, additional antibiotic prophylactic doses are recommended to maintain an adequate plasma concentration.⁶

During some dental procedures, it may be necessary to use hemostatic measures such as gauze compression, sutures, gelatin, or collagen sponges.^{34,43,44} Antifibrinolytic substances such as tranexamic acid, a synthetic derivative of the amino acid lysine, can be administered.⁵² Patients must use mouthwash by rinsing with 4.8% concentration solution for 2 min four times daily, for 1 week.^{34,52}

In patients who require urgent or emergent cardiac surgery, the need for a dental intervention should be discussed by all members of the heart team including cardiology, cardiac surgery, and anesthesia in consultation with the dental service. Important factors to be evaluated include the severity of both the underlying cardiovascular and dental disease, the time necessary for any dental intervention, and what if any alternative, less invasive procedures can be performed to temporize the dental issues.

An important issue is how long one has to wait after an extraction, or any other dental procedure, to undergo cardiac surgery. Based on studies showing duration of bacteremia post-dental intervention, the recommendation is to wait at least 24 h after dental treatment before proceeding with a medical intervention in these patients.^{47,53} Most studies have shown that following tooth extractions, bacteria is present in the majority of blood cultures^{12,47,54} but significantly decreases 10–60 min after dental interventions.^{55–57} In rare cases, it was possible to detect positive blood cultures up to 24 h.⁴⁷ However, several authors have reported no differences in adverse outcomes in patients who had their dental procedures performed before or concomitantly with the cardiac surgery.^{53,58}

CONFLICTS OF INTEREST

None.

ORCID

Tarcilia A. Silva  <http://orcid.org/0000-0001-9623-7835>

REFERENCES

1. Thuny F, Grisoli D, Collart F, et al. Management of infective endocarditis: challenges and perspectives. *Lancet*. 2012;379: 965–975.

2. Ribeiro FFF, Arruda GDS, Ptak DM, et al. Seguimento pós-operatório de cirurgia valvar. *Rev Bras Cardiol.* 2013;26:112–119.
3. Boeder NF, Dörr O, Rixe J, et al. Endocarditis after interventional repair of the mitral valve: review of a dilemma. *Cardiovasc Revasc Med.* 2017;18:141–144.
4. Stephans JL, Boulemeden A, Richons D, Turner DP. Prosthetic valve endocarditis following dental extractions. *J Card Surg.* 2016;31:321–323.
5. Carmona T, Posse JL, Dios PD, et al. Bacterial endocarditis of oral etiology in an elderly population. *Arch Gerontol Geriatr.* 2003;36:49–55.
6. Wilson W, Taubert KA, Gewitz M, et al. Prevention of infective endocarditis. *Circulation.* 2007;9:1736–1754.
7. Duval X, Lepout C, Danchin N. The new American Heart Association guidelines on the prevention of infective endocarditis: culmination of a long process of thought. *Heart.* 2008;94:715–716.
8. Khan IA, Ijaz N. Prophylaxis of infective endocarditis: current perspectives. *Int J Cardiol.* 2009;134:e105–e106.
9. Nunes MCP, Gelape CL, Ferrari TCA. Profile of infective endocarditis at a tertiary care center in Brazil during a seven-year period: prognostic factors and in-hospital outcome. *Int J Infect Dis.* 2010;14:394–398.
10. Rosa MRM, Cosano LC, Perez MJR, et al. The bacteremia of dental origin and its implications in the appearance of bacterial endocarditis. *Med Oral Patol Oral Cir Bucal.* 2014;19:67–73.
11. Araújo IR, Ferrari TCA, Teixeira-Carvalho A, et al. Cytokine signature in infective endocarditis. *PLoS ONE.* 2015;10:1–14.
12. Barbosa M, Prada López I, Álvarez M, et al. Post-tooth extraction bacteraemia: a randomized clinical trial on the efficacy of chlorhexidine prophylaxis. *PLoS ONE.* 2015;10:1–15.
13. Dentino A, Lee S, Mailhot J, et al. Principles of periodontology. *Periodontol.* 2013;61:16–53.
14. Horliana ACRT, Chambrone L, Foz AM, et al. Dissemination of periodontal pathogens in the bloodstream after periodontal procedures: a systematic review. *PLoS ONE.* 2014;9:e98271.
15. Mougeot FK, Saunders SE, Brennan MT, et al. Associations between bacteremia from oral sources and distant-site infections: tooth brushing versus single tooth extraction. *Oral Surg Oral Med Oral Pathol Oral Radiol.* 2015;119:30–35.
16. Souza AF. Identificação de condições de saúde bucal em pacientes submetidos à cirurgia cardíaca: monitoramento de prováveis fatores de risco para Endocardite. Dissertação (Mestrado) – Universidade Federal de Minas Gerais. Faculdade de Odontologia, 2016; 1–111. Accessed May 28, 2017 from: http://www.bibliotecadigital.ufmg.br/dspace/bitstream/handle/1843/BUBD-A8PLEL/disserta_o_vers_o_final_2016.pdf?sequence=1.
17. North West Medicines Information Centre. Surgical Management of the primary care dental patient on Warfarin. UK Medicines Information 2007. Accessed May 23, 2017 from: <http://www.app.dundee.ac.uk/tuith/Static/info/warfarin.pdf>.
18. Douketis JD, Spyropoulos AC, Spencer FA et al. Perioperative management of antithrombotic therapy antithrombotic therapy and prevention of thrombosis, 9th ed: American College of Chest Physicians Evidence-Based Clinical Practice Guidelines. *Chest.* 2012;141:e326S–e350S.
19. Souza AF, Rocha AL, Castro WH et al. Dental care before cardiac valve surgery: is it important to prevent infective endocarditis? *Int J Cardiol Heart Vasc.* 2016;12:57–62.
20. Nakamura Y, Tagusaria O, Seikea Y et al. Prevalence of periodontitis and optimal timing of dental treatment in patients undergoing heart valve surgery. *Interact Cardiovasc Thorac Surg.* 2011;12:696–700.
21. Deppe H, Auer-Bahrs J, Kolk A et al. Need for dental treatment following cardiac valve surgery: a clinical study. *J Craniomaxillofac Surg.* 2007;35:293–301.
22. Terezhalmay GT, Safadi TJ, Longworth DL et al. Oral disease burden in patients undergoing prosthetic heart valve implantation. *Ann Thorac Surg.* 1997;63:402–404.
23. Baddour LM, Wilson WR, Bayer AS et al. Infective endocarditis in adults: diagnosis, antimicrobial therapy, and management of complications: a scientific statement for healthcare professionals from the American Heart Association. *Circulation.* 2015;132:1435–1486.
24. S Secretaria S de Saúde S de São S Paulo. S Manual S de Odontologia S Hospitalar. F 1ª C ed. 2012. C 86p. Accessed May 28, 2017 from: http://www.saude.sp.gov.br/resources/ses/perfil/profissional-da-saude/grupo-tecnico-de-aco-es-estrategicas-gtae/manual-de-odontologia-hospitalar/manual_odonto.pdf.
25. Yamagata K, Onizawa K, Yanagawa T et al. A prospective study to evaluate a new dental management protocol before hematopoietic stem cell transplantation. *Bone Marrow Transplant.* 2006;38:237–242.
26. Nishimura RA, Otto CM, Bonow RO et al. AHA/ACC guideline for the management of patients with valvular heart disease: a report of the American College of Cardiology/American Heart Association Task Force on Practice Guidelines. *Circulation.* 2014;129:8–235.
27. Habib G, Lancellotti P, Antunes MJ et al. ESC guidelines for the management of infective endocarditis: the Task Force for the Management of Infective Endocarditis of the European Society of Cardiology (ESC). Endorsed by: European Association for Cardio Thoracic Surgery (EACTS), The European Association of Nuclear Medicine (EANM). *Eur Heart J.* 2015;36:3075–3123.
28. Sherman-Weber S, Axelrod P, Suh B et al. Infective endocarditis following orthotopic heart transplantation: 10 cases and a review of the literature. *Transpl Infect Dis.* 2004;6:165–170.
29. Nishimura RA, Otto CM, Bonow RO et al. 2017 AHA/ACC focused update of the 2014 AHA/ACC guideline for the management of patients with valvular heart disease: a report of the American College of Cardiology/American Heart Association Task Force on Clinical Practice Guidelines. *Circulation.* 2017;135:e1159–e1195.
30. Dajani AS, Taubert KA, Wilson W et al. Prevention of bacterial endocarditis: recommendations by the American Heart Association. *JAMA.* 1997;277:1794–1801.
31. Tarasoutchi F, Montera MW, Grinberg M et al. Diretriz Brasileira de Valvopatias – SBC 2011/I Diretriz Interamericana de Valvopatias – SIAC 2011. *Arq Bras Cardiol.* 2011;97:1–67.
32. Serrano JRCV, Felon G, Soeiro AM et al. Diretrizes Brasileiras de Antiagregantes Plaquetários e Anticoagulantes em Cardiologia. *Arq Bras Cardiol.* 2013; 101: 1–93.
33. Fakhri HR, Janket SJ, Jackson EA et al. Tutorial in oral antithrombotic therapy: biology and dental implications. *Med Oral Patol Oral Cir Bucal.* 2013 18: e461–e472.
34. Wahl MJ, Pinto A, Kilham J et al. Dental surgery in anticoagulated patients: stop the interruption. *Oral Surg Oral Med Oral Pathol Oral Radiol.* 2015;119:136–157.
35. Whitlock RP, Sun JC, Frenes SE, et al. Antithrombotic and thrombolytic therapy for valvular disease: antithrombotic therapy and prevention of thrombosis, 9th ed: American College of Chest Physicians Evidence-Based Clinical Practice Guidelines. *Chest.* 2012; 141:e576S–e600S.
36. Dental Practitioners' Formulary. British Medical Association and Royal Pharmaceutical Society of Great Britain. London: British Dental Association; 2002–2004. D8. p 117–119.
37. Scully C, Cawson RA. *Medical problems in dentistry.* 5th ed. Edinburgh: Elsevier Churchill Livingstone; 2005. p 150.
38. Randall C. Surgical management of the primary care dental patient on warfarin. *Dent Update.* 2005;32:419–420.
39. Salam S, Yusuf H, Milosevic A. Bleeding after dental extractions in patients taking warfarin. *Br J Oral Maxillofac Surg.* 45;2007 463–466.
40. Blinder D, Manor Y, Martinowitz U et al. Dental extractions in patients maintained on continued oral anticoagulant: comparison of local

- haemostatic modalities. *Oral Surg Oral Med Oral Pathol Oral Radiol Endod.* 1999;88:137–140.
41. Evans IL, Sayers MS, Gibbons AJ et al. Can warfarin be continued during dental extraction? Results of a randomized controlled trial. *Br J Oral Maxillofac Surg.* 2002;40:248–252.
 42. Alquwaizani M, Buckley L, Adams C et al. Anticoagulants: a review of the pharmacology, dosing and complications. *Curr Emerg Hosp Med Rep.* 2013;1:83–97.
 43. Karsli ED, Erdogan O, Esen E et al. Warfarin and heparin in dental extraction. *J Oral Maxillofac Surg.* 2011;69:2500–2507.
 44. Bajkin BV, Bajkin IA, Petrovic BB. The effects of combined oral anticoagulant-aspirin therapy in patients undergoing tooth extractions: a prospective study. *J Am Dent Assoc.* 2012;143:771–776.
 45. Berchier CE, Slot DE, Van der Weijden GA. The efficacy of 0.12% chlorhexidine mouthrinse compared with 0.2% on plaque accumulation and periodontal parameters: a systematic review. *J Clin Periodontol.* 2010;37:829–839.
 46. Tomás I, Alvarez M, Limeres J et al. Effect of a chlorhexidine mouthwash on the risk of post extraction bacteremia. *Infect Control Hosp Epidemiol.* 2007;28:577–582.
 47. Ugwumba CU, Adeyemob WL, Odeniyic OM et al. Preoperative administration of 0.2% chlorhexidine mouthrinse reduces the risk of bacteraemia associated with intra-alveolar tooth. *J Craniomaxillofac Surg.* 2014;42:783–1788.
 48. Zimmermann C, Meurer MI, Grando LJ et al. Dental treatment in patients with leukemia. *J Oncol.* 2015;2015:1–14.
 49. Neves RS, Neves ILI, Giorgi DMA et al. Effects of epinephrine in local dental anesthesia in patients with coronary artery disease. *Arq Bras Cardiol.* 2007;88:482–487.
 50. Laragnoit AB, Neves RS, Neves ILI et al. Locoregional anesthesia for dental treatment in cardiac patients: a comparative study of 2% lain lidocaine and 2% lidocaine with epinephrine (1:100,000). *Clinics.* 2009;64:177–182.
 51. Renton T, Woolcombe S, Taylor T, Hill CM. Oral surgery: part 1. Introduction and the management of the medically compromised patient. *Br Dent J.* 2013;215:213–223.
 52. Carter G, Goss A. Tranexamic acid mouthwash—a prospective randomized study of a 2-day regimen vs 5-day regimen to prevent postoperative bleeding in anticoagulated patients requiring dental extractions. *Int J Oral Maxillofac Surg.* 2003;32:504–507.
 53. Lockhart PB, Brennan MT, Cook WH et al. Concomitant surgical treatment of dental and valvular heart diseases. *Oral Surg Oral Med Oral Pathol Oral Radiol Endod.* 2009;107:71–76.
 54. Lockhart PB, Brennan MT, Sasser HC et al. Bacteremia associated with tooth brushing and dental extraction. *Circulation.* 2008;117:3118–3125.
 55. Lockhart PB, Brennan MT, Kent ML et al. Impact of amoxicillin prophylaxis on the incidence, nature, and duration of bacteremia in children after intubation and dental procedures. *Circulation.* 2004;109:2878–2884.
 56. Heimdahl A, Hall G, Hedberg M et al. Detection and quantitation by lysis-filtration of bacteremia after different oral surgical procedures. *J Clin Microbiol.* 1990;28:2205–2209.
 57. Rajasuo A, Perkki K, Nyfors S et al. Bacteremia following surgical dental extractions with an emphasis on anaerobic strains. *J Dent Res.* 2004;83:170–174.
 58. Lam D, Wright K, Archer B. Is it Safe to perform dental and cardiac valve surgeries concomitantly? *J Oral Maxillo Fac Surg.* 2013;71:1000–1004.

How to cite this article: Souza AF, Rocha AL, Castro WH, et al. Dental management for patients undergoing heart valve surgery. *J Card Surg.* 2017;1–6.
<https://doi.org/10.1111/jocs.13211>

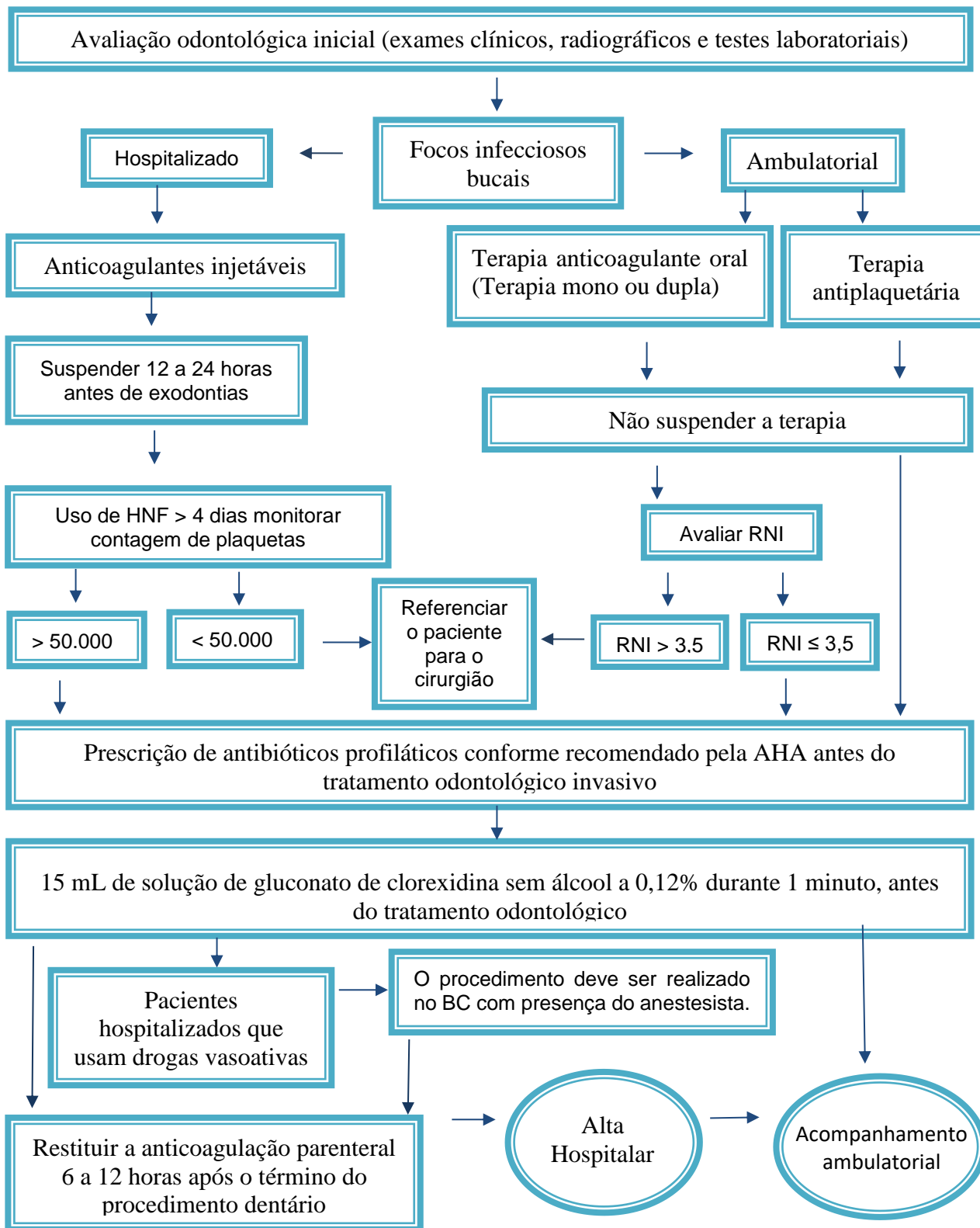


Figura 1 - Algoritmo manejo odontológico para pacientes submetidos à cirurgia cardíaca valvar. Traduzido de Souza et al., 2017.

Abreviaturas: AHA, American Heart Association; INR, Razão Internacional Aleatória; HNF, heparina não fraccionada; BC, Bloco Cirúrgico.